

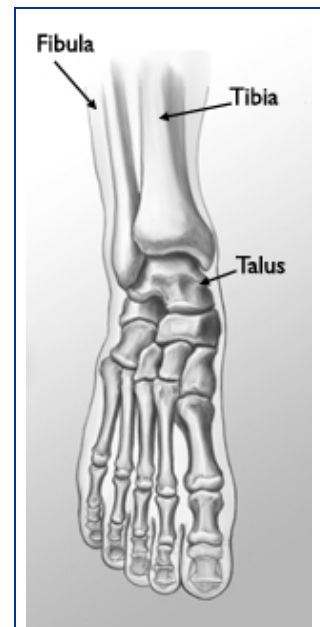
## Ankle Fractures In Children

A broken ankle, also called an ankle fracture, is a common childhood injury. An ankle fracture is a break in one or more of the bones that make up the ankle: the tibia, fibula, and talus.

Ankle fractures in children are more likely to involve the tibia and fibula (the long bones in the lower leg) than the talus (a smaller bone in the foot). Fractures at the ends of the tibia and fibula typically involve the growth plates. Growth plates are areas of developing cartilage tissue that regulate bone growth and help determine the length and shape of the adult bone.

Growth plate fractures in the ankle often require immediate attention because the long-term consequences may include legs that grow crooked or of unequal length.

An orthopaedic surgeon will provide counseling about treatment options, as well as longer term follow-up care to monitor the outcome of the treatment.



The normal skeletal anatomy of the foot and ankle.

*Reproduced and modified with permission from The Body Almanac. © American Academy of Orthopaedic Surgeons, 2003.*

As discussed above, three bones form the ankle joint:

- Tibia (shinbone)
- Fibula (smaller bone in the lower leg)
- Talus (small foot bone that works as a hinge between the tibia and fibula)

Bones are connected to other bones by ligaments. Ligaments act like strong ropes to hold the bones together. There are several ligaments in the ankle to help keep the joint stable.

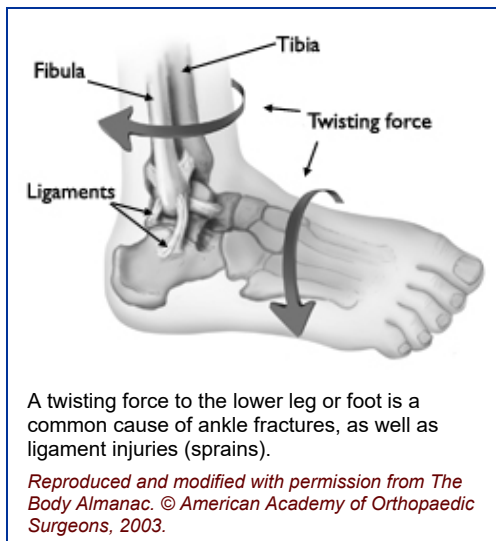
## Cause

---

### **Twisting Force**

Pediatric ankle injuries typically occur during sports or vigorous play when a child's lower leg or foot twists unexpectedly.

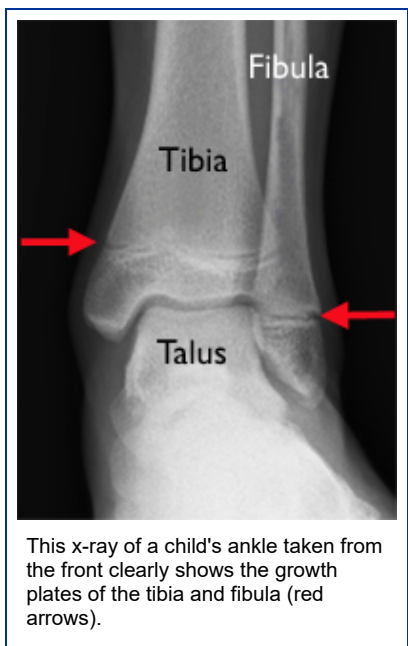
Sports involving lateral motion and jumping — like basketball — may put children at higher risk for ankle injuries. For example, when jumping to defend, shoot, or rebound, a child may land on another child's foot, causing the foot to twist or roll to the inside or outside.



### **Growth Plates**

The long bones of the body do not grow from the center outward. Instead, growth occurs at each end of the bone around the growth plate. When a child becomes full-grown, the growth plates harden into solid bone.

Because growth plates are the last portion of bones to harden, they are vulnerable to fracture. In fact, the ligaments that attach the tibia and fibula to the talus bone are generally stronger than the growth plates. This is why an ankle twist that would result in a sprain in an adult is more likely to cause a growth plate fracture in a child.



Pediatric ankle fractures account for 9% to 18% of all growth plate fractures. In children age 10 to 15 years, only injuries to the wrist and hand are more common than ankle fractures. These older children are more likely to participate in strenuous sports activities, and their growth plates are not yet fully mature.

## Symptoms

---

Without an x-ray, it is often difficult to differentiate between an ankle sprain and a more serious ankle fracture. Initially, both sprains and fractures may cause pain and swelling.

A strong sign of a fracture, however, is when a child cannot put weight on the injured ankle.

Any fracture with an open skin wound is cause for significant concern, and the injured child should be taken to the nearest emergency room or urgent care facility as soon as possible.

## Doctor Examination

---

After discussing your child's medical history and how the injury occurred, your doctor will do a careful examination. Your doctor will look for:

- Swelling and tenderness
- Bruising
- A deformed or crooked appearance of the ankle
- Tears or openings in the skin

Skin wounds are a sign of a potential open fracture. This type of fracture is particularly serious because once the skin is broken through, infection in both the wound and the bone can occur. To prevent infection, open fractures require immediate treatment, including irrigation to clear the wound of debris and bacteria, and surgery to repair the fracture.

During the physical examination, your doctor will feel for pulses in your child's leg and foot. He or she will also check for sensation (feeling) and movement.

## Tests

---

If your doctor suspects an ankle fracture, he or she will order additional tests to provide more information about your child's injury.

### **X-rays**

The most common way to evaluate a fracture is with x-rays, which provide clear images of bone. X-rays will usually show whether a bone is intact or broken.

### **Magnetic Resonance Imaging (MRI)**

If the physical examination suggests a fracture but the x-rays do not show it, your doctor may order a magnetic resonance imaging (MRI) scan. These tests provide high resolution images of both bones and soft tissues, like ligaments.

### **Computed Tomography (CT)**

This type of scan can create a cross-section image of the ankle. It is especially useful when the fracture extends into the ankle joint.

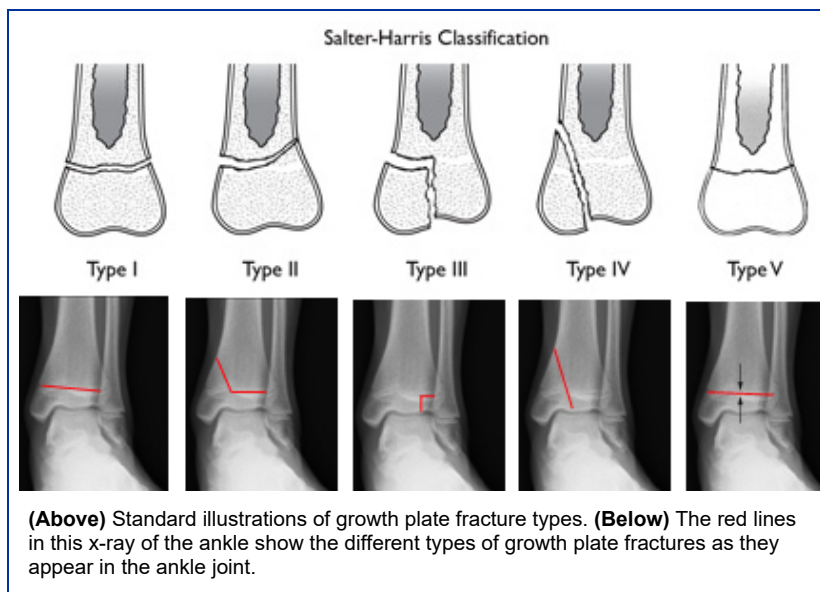
## Types of Pediatric Ankle Fractures and Treatment

Pediatric ankle fractures are generally classified based on several factors, including:

- The location of the fracture
- The degree of damage to the growth plate
- The position of the foot at the time of injury, such as pronation (Lauge-Hansen classification system)
- The direction of the force at the time of the injury, such as external rotation (Lauge-Hansen classification system)

When planning treatment, your doctor will take these factors into account. He or she will also consider the degree of bone displacement. In a displaced fracture, the broken ends of bone are separated and do not line up. These types of fractures often require surgery to put the pieces back together.

Perhaps the most widely used classification system for growth plate fractures is the Salter-Harris system. For the purposes of this article, the Salter-Harris system will be used to describe several types of fractures and treatment options.



### **Salter-Harris I and II Fractures**

Type I fractures break through the bone at the growth plate, separating the bone end from the bone shaft and completely disrupting the growth plate. Type II fractures break through part of the bone at the growth plate and crack through the bone shaft, as well.

Both of these types of fractures have a low risk for impairing growth.

First, your doctor will put the pieces of broken bone back into place, called a closed reduction. This is typically done while your child is under sedation or anesthesia. A cast will keep the bones in place while they heal, and is usually needed for 4 to 6 weeks.

In some cases, closed reduction is unsuccessful. This occurs most often because soft tissue, like muscle, gets in between the healing bones. If this happens, surgery is required. During the procedure — called an open reduction — the soft tissue is removed, the bones are realigned and usually held in place with internal fixation (such as pins and screws).

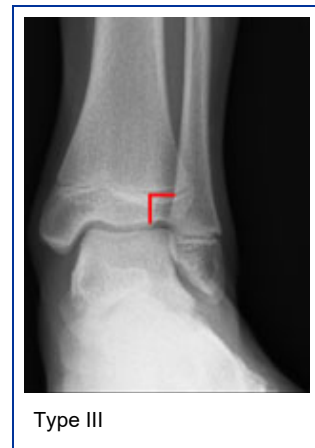Follow-up care is needed to ensure healing and normal bone growth.

### **Salter-Harris III Fractures**

These fractures cross through a portion of the growth plate and break off a piece of the bone end. They often damage the growth plate.

Long-term risks are that the joint will not heal properly, and that growth will be uneven, leading to a crooked ankle.

Your doctor will first align the broken bones during a closed reduction procedure. If after the closed reduction there is more than 2 millimeters of displacement between the broken bones, your doctor will recommend surgery using screws or pins to fix the broken ends in place.

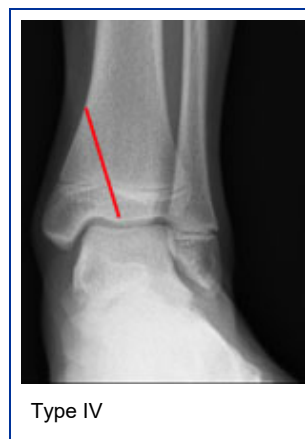

### **Salter-Harris IV Fractures**

These fractures break through the bone shaft, the growth plate, and the end of the bone.

Patients with non-displaced fractures are treated with closed reduction and a non-weight-bearing long-leg cast, followed by a short-leg walking cast.

If a closed reduction results in more than a 2-millimeter "step off" — meaning that the broken piece juts out along the bottom surface of the bone — then surgery is necessary. Open reduction and pins and/or screws will more accurately align the broken pieces and reduce damage to the articular cartilage that protects the end of the bone.



Type IV ankle fractures of the tibia are often seen together with triplane fractures (see below), shearing injuries to the bone on the inside of the ankle, and fibular fractures.

### **Salter-Harris V Fractures**

These fractures result from a crushing injury to the growth plate from a compression force. They are rare fractures that are difficult to initially diagnose. Growth problems are a major concern with Type V fractures.



In many cases, these fractures are diagnosed months or years after the injury when leg-length discrepancy or angular deformity has already developed. Treatment at this point aims to correct leg-length discrepancy or deformity.

### **Distal Fibular Fractures**

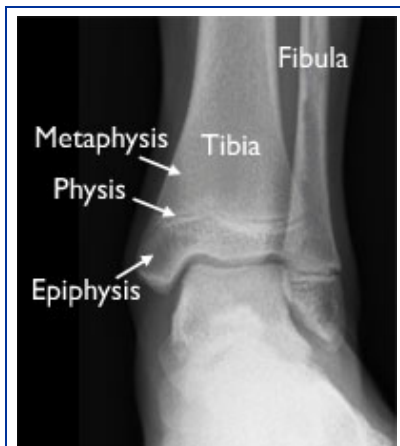
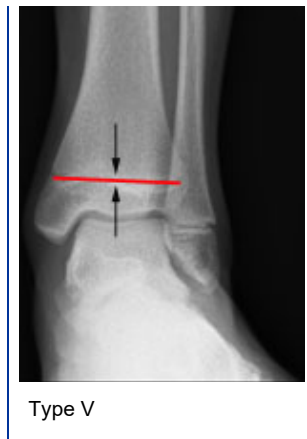When just the fibula is injured in the ankle, it is most often a Salter-Harris Type I or II fracture. These isolated fractures most often result from low-energy trauma, such as a fall from standing height. Isolated distal fibular fractures generally heal well when treated with a short-leg walking cast.

### **Special Distal Tibial Fractures**

The growth plate at the ankle end of the tibia (called the distal end of the tibia) matures and goes away in girls at about 14 years of age, and in boys at about age 16. This occurs over an 18-month transitional period. During this time, the growth plate first begins to close and harden in the center of the bone, then outward toward the front, then toward the back, and finally all around the outside of the bone.

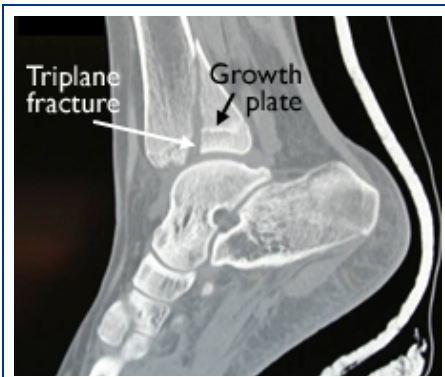
It is during this period that "transitional fractures" of the maturing growth plate can occur. Two common transitional fractures of the distal tibia are triplane fractures and Tillaux fractures.

**Triplane Fractures.** If the fracture extends away from the growth plate in both directions (into the distal tibia as well as into the joint) it is a triplane fracture. Triplane fractures extend through the epiphysis, physis (growth plate), and metaphysis of the bone.



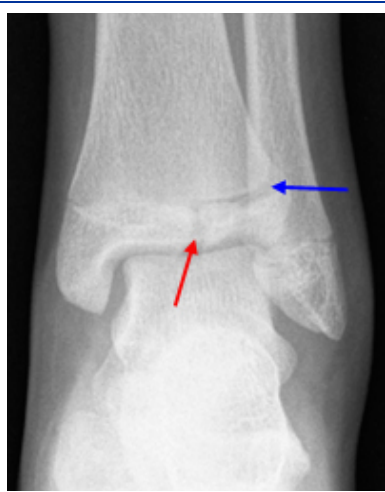
The distal tibia of a growing child is comprised of three sections: the physis, epiphysis, and metaphysis.

Treatment of triplane fractures depends on the amount of displacement between the broken bones. Minimally displaced fractures (less than 2 millimeters) and non-displaced fractures can be treated with a long-leg cast.

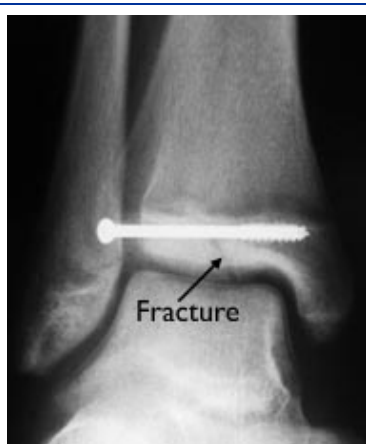


This CT scan of the ankle taken from the side shows a triplane fracture.

**Tillaux fractures.** Ankle fractures occurring in the front and outside area of the distal tibia in adolescents are named after the French surgeon Tillaux. This is a Salter-Harris Type III fracture which extends through the growth plate and joint. Tillaux fractures account for 3% to 5% of pediatric ankle fractures.



This x-ray of the ankle taken from the front shows a Tillaux fracture. The blue arrow shows a widening of the growth plate, and the red arrow shows the fracture extending through the epiphysis and into the joint.



In this x-ray, a Tillaux fracture has been treated with a screw fixation.

## Long-Term Outcomes

---

Growth plate fractures must be watched carefully by your doctor to ensure proper long-term results. This is because these fractures can lead to ankle deformity if the growth is uneven.

Regular follow-up visits to your doctor should continue for at least a year after the fracture. Complicated fractures (such as Types III, IV, and V) may need to be followed until the child reaches skeletal maturity.

Last reviewed: March 2012



Reviewed by members of POSNA (Pediatric Orthopaedic Society of North America)

*The Pediatric Orthopaedic Society of North America (POSNA) is a group of board eligible/board certified orthopaedic surgeons who have specialized training in the care of children's musculoskeletal health. One of our goals is to continue to be the authoritative source for patients and families on children's orthopaedic conditions. Our Public Education and Media Relations Committee works with the AAOS to develop, review, and update the pediatric topics within OrthoInfo, so we ensure that patients, families and other healthcare professionals have the latest information and practice guidelines at the click of a link.*

AAOS does not endorse any treatments, procedures, products, or physicians referenced herein. This information is provided as an educational service and is not intended to serve as medical advice. Anyone seeking specific orthopaedic advice or assistance should consult his or her orthopaedic surgeon, or locate one in your area through the AAOS ["Find an Orthopaedist"](#) program on this website

Copyright 2012 American Academy of Orthopaedic Surgeons

## Related Articles

Care of Casts and Splints (<http://orthoinfo.aaos.org/topic.cfm?topic=A00095>)

Fractures (Broken Bones) (<http://orthoinfo.aaos.org/topic.cfm?topic=A00139>)

Growth Plate Fractures (<http://orthoinfo.aaos.org/topic.cfm?topic=A00040>)

Huesos saludables en todas las edades (Healthy Bones at Every Age) (<http://orthoinfo.aaos.org/topic.cfm?topic=A00721>)

Internal Fixation for Fractures (<http://orthoinfo.aaos.org/topic.cfm?topic=A00196>)

Limb Length Discrepancy (<http://orthoinfo.aaos.org/topic.cfm?topic=A00259>)

Open Fractures (<http://orthoinfo.aaos.org/topic.cfm?topic=A00582>)

### OrthoInfo

The American Academy of Orthopaedic Surgeons  
9400 West Higgins Road  
Rosemont, IL 60018  
Phone: 847.823.7186  
Email: [orthoinfo@aaos.org](mailto:orthoinfo@aaos.org)