

Anterior Knee Pain Syndrome

What is anterior knee pain?

Pain around the front of the knee is often referred to as patellofemoral pain. This pain may be caused by soft cartilage under the kneecap (patella), abnormal tracking (or alignment) of the kneecap, an irritation of the soft tissues around the front of the knee, or referred pain from other areas such as the back or hip. It is one of the most common causes of knee pain in young active patients. Symptoms typically wax and wane for long periods of time, and are worse with squatting, stairs, and prolonged sitting. Patients may or may not have a specific history of trauma.

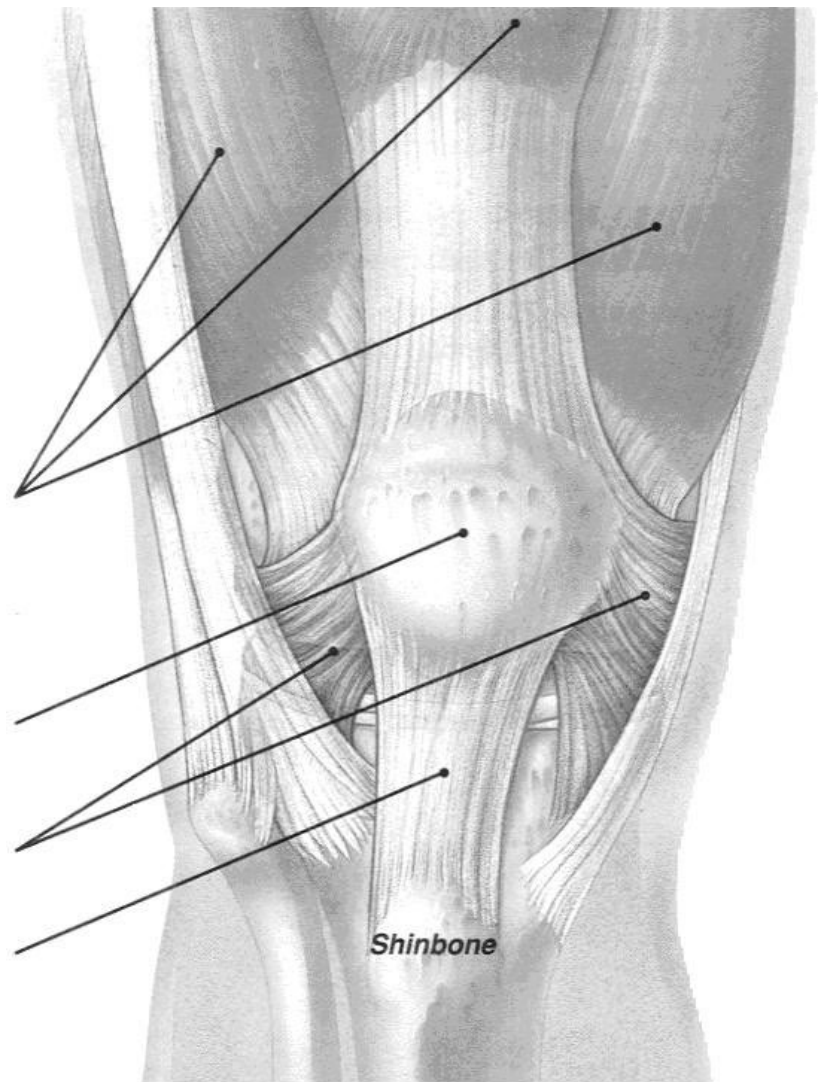
The knee cap (patella) is a flat triangular bone about two inches wide. It is just one of several parts that make up the knee joint. Other parts of the knee are muscles, tendons, ligaments and cartilage. The kneecap plays a special role: it protects the knee joint and also gives your muscles the extra leverage they need to straighten the leg more efficiently.

Quadriceps muscles at the front of your thigh hold the kneecap against the thigh bone and help straighten the leg. Other muscles on the inside of your thigh (**adductors**), back of your thigh (**hamstrings**), and back of your shin (**calves**) help the quadriceps move your leg.

The **kneecap (patella)** anchors your quadriceps muscles as they contract, and protects the bones and other tissues underneath it.

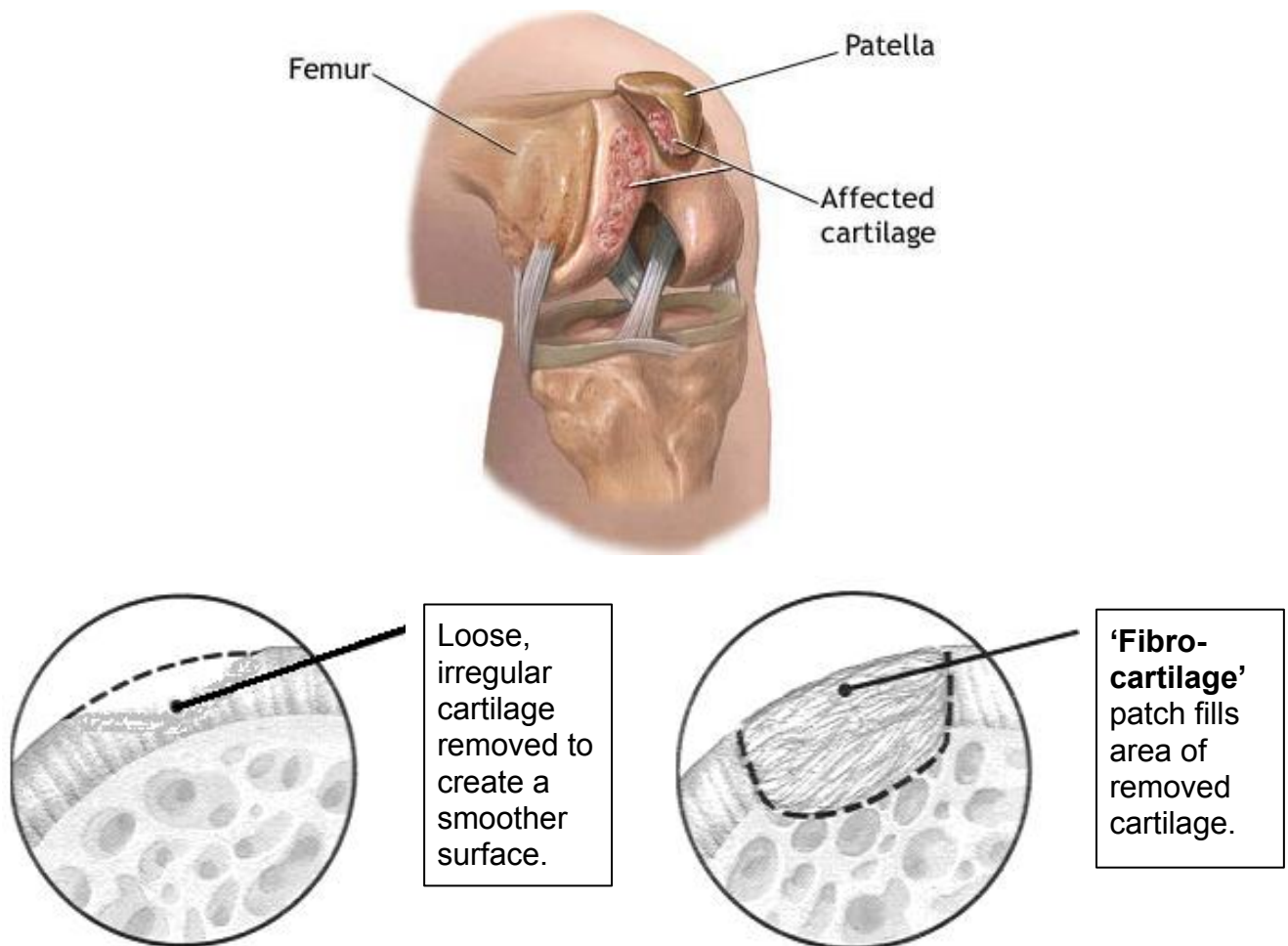
Retinacula are fibrous bands on the sides of the kneecap. They help hold the kneecap in place.

The patellar tendon is a fibrous cord that connects the patella to the shinbone.



Chondromalacia

Chondromalacia refers to the softening and breakdown of the lining cartilage under the kneecap. This actually represents an early stage of arthritis. It may be caused by trauma, overuse, or malalignment. Many times the exact reason people develop this condition is unknown, and genetic factors may play a role. Conservative treatment is similar to that for patellar malalignment. In addition, oral supplements such as glucosamine and chondroitin sulfate may slow the cartilage breakdown and provide symptomatic relief. If swelling or “fluid on the knee” develops, removing the fluid and injecting a steroid into the joint is helpful. Newer injections that provide a lubricant to the joint are also available. If conservative treatment fails to decrease symptoms, surgery may be indicated. This usually involves an arthroscopic surgery to remove loose cartilage and smooth the undersurface of the kneecap. While this does not put normal cartilage back into the damaged areas, it can be quite helpful in providing pain relief and better function for many years.

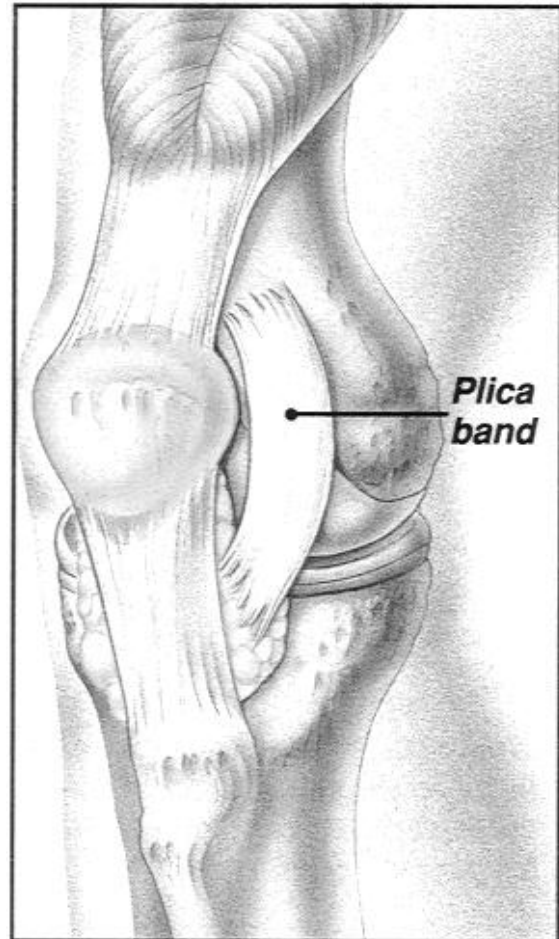


Plica

Plica Bands are elastic fibers inside the knee that usually run along the side of the kneecap. These bands usually disappear early on in childhood. However, in some people the bands never go away.

These bands usually do not cause any problems and most people do not even notice them. Occasionally the bands become irritated and inflamed; this may cause them to become thickened and possibly painful. They will sometimes cause “popping” or “snapping” of the knee.

Symptoms usually respond to rest, icing, anti-inflammatory medication, and physical therapy. Occasionally a steroid injection may be used to reduce swelling. In rare cases the symptoms persist or recur, requiring an arthroscopic surgery to remove the plica band.



Your sports medicine doctors at the University of South Florida have extensive experience in dealing with anterior knee pain syndrome. We understand that the chronic nature of this problem is frustrating for all. As our patient, you can be assured of the best treatment available today.